

Fat Transfer Techniques: General Concepts

Edward D. Buckingham, MD¹

¹ Director, Buckingham Center for Facial Plastic Surgery, Austin, Texas
 Facial Plast Surg 2015;31:22–28.

Address for correspondence Edward D. Buckingham, MD,
 Department of Facial Plastic Surgery, Buckingham Center for Facial
 Plastic Surgery, 2745 Bee Caves Road, Suite 101 Austin, Texas 78746
 (e-mail: edbuckin@yahoo.com).

Abstract

Facial volume loss has become widely accepted as one of the contributing factors in global facial aging. Some have even suggested that bony, muscular, fatty, and dermal/epidermal changes are more integral in the aging process than gravitational influence. Although detractors of autologous fat transfer persist, facial autologous fat transfer has become widely utilized as one option for volume restoration. Various techniques in harvesting, processing, and injecting autologous fat have been debated at length without clear guidelines emerging to maximize outcomes. This article aims to present one surgeon's experience in successful fat grafting philosophy and technique. Areas covered will include preparation, harvesting, processing, and injection techniques. The injection techniques are organized by facial region and into the general philosophy and thinking regarding the facial region as well as the specific technique that has been utilized over 7 years and hundreds of successful procedures.

Keywords

- ▶ facial volume loss
- ▶ facial aging
- ▶ volume replacement
- ▶ autologous fat transfer

Facial volume loss has become an ever increasing area of interest in facial aging with an enormous amount of research and lecture material presented documenting facial volume-related changes from youth to old age.^{1–8} Basic science research has confirmed that volume changes occur in all three-dimensional components of the face including bone, soft tissue, and skin.^{9–11} Many more articles and much attention has been directed toward techniques aimed at restoring lost volume and entire segments of industry have been developed to create, produce, and market products all designed to restore a youthful appearance by replacing lost volume. Although several years ago patients would present with complaints of “eyelid bags,” now it is more common for the complaint of “hollow eyes” to be expressed. Surgical techniques have also been developed to restore facial volume by lifting fat pads or repositioning fat pads into a more youthful location. One of the more controversial procedures historically has been autologous fat grafting, whereby the patient's own fat cells are harvested from other parts of the body using cannulas, various processing of the harvested fat occurs, and then the fat parcels are reinjected into the face where vascular in-growth occurs and the adipocytes become a living integrated part of the face. The procedure has been controversial over the years because of varying results and

arguments over longevity. With more research and improved techniques, the detracting arguments are becoming rare and the popularity of fat grafting has increased significantly. This article aims to describe the general concepts and specific techniques utilized by the author to yield relatively consistent outcomes in facial autologous fat grafting.

Patient Consultation

One of the most important aspects of successful fat grafting has nothing to do with the procedure or technique, but rather the interaction between the surgeon and patient at the time of consultation. Important aspects of the consultation include explaining the concept of facial volume loss to the patient, demonstrating on their face the areas of volume loss and the goals to be sought, demonstrating results in previous patients and most of all setting expectations regarding recovery and results. The concepts of facial volume loss are explained in detail elsewhere in this issue, but of relevance and importance to this article are the discussion of recovery and the setting expectation of results.

In our practice, autologous fat transfer is most often performed with other surgical procedures such as blepharoplasty and rhytidectomy. This results from the conversation

about recovery. Autologous fat transfer, depending on the areas to be transferred and the volume of fat transferred carries a minimum of 1 week to be socially active and possibly as long as 3 weeks. Therefore, it makes most sense to combine the procedure with other desired procedures that also require social downtime. For patients who are looking to have shorter recovery, volume restoration usually makes more sense to be performed with a variety of “off the shelf” filling agents. Having said that, there exists a percentage of patients who are not interested in temporary fillers, desire the potential permanence of autologous fat transfer, and also do not desire other surgical interventions. In these cases, autologous fat transfer may be performed as an independent procedure. Setting expectations regarding results is the most important aspect of the consultation. Each patient is informed that an autologous fat transfer is a graft, that is, which we are taking living adipocytes from one part of the body, removing them from their blood supply, and grafting them to a new location, where vascular in-growth must occur in order for the cells to survive and last. The patient is informed that there is a range of survival percentage from patient to patient, and that while some result is almost always the case, a perfect result may only occur a portion of the time and a secondary fat transfer or touch up with injectable fillers may be required, although the fat graft will provide at least a base layer and reduce the amount of filler requirement, if needed at all. It is our belief that the grafted fat becomes vascularized, provides a long-term benefit, and personally have patients 7 years postprocedure with a significant remaining benefit (►Fig. 1A–I).

Anesthesia, Donor Site Preparation, and Harvesting

Full face autologous fat transfer where upper, mid, and lower face are all grafted is usually performed under intravenous sedation consisting of a benzodiazepine, narcotic, and propofol supplemented with local anesthesia. Smaller fat transfers including secondary transfers which are usually to isolated regions are performed with an oral cocktail of benzodiazepine and hydrocodone or tramadol. The donor area is marked out in the preoperative area with the patient standing; the donor site preference being abdominal followed by outer thigh and then inner thigh in female patients and abdomen followed by a flank or lower back fat for men. The abdominal area is chosen first as no added positioning is required. All of the other areas involve moving the patient from side to side to complete the harvest. Once the patient has the onset of systemic anesthesia, the donor site is injected with a mixture of 1% Xylocaine with 1:100,000 epinephrine and equal parts normal saline producing a solution of 0.5% Xylocaine with 1:200,000 epinephrine. A 3-inch 25-gauge spinal needle on a 20 mL syringe is inserted in the subdermal plane and approximately 10 mL per hemiabdomen or each thigh is injected. The remaining 10 mL is injected just above the muscle fascia (►Fig. 2). The midcutaneous plane is avoided as lidocaine is thought to cause some adipocyte toxicity and very little added benefit to analgesia is provided in this space. Approximately 10 minutes is allowed for

vasoconstriction to occur while the facial area is injected and skin preparation performed. A #15 blade is utilized to make a small stab incision in the midline lower abdomen, horizontal gluteal crease, inguinal region, or lateral waste area depending on the donor site. If bilateral donor sites are utilized equal amounts are harvested unless there is an obvious preexisting asymmetry. A 3 mm diameter 15 cm length Tenard type cannula is utilized for harvesting. A bullet tip cannula was utilized in the past, but the smaller injection cannulas and Puregraft processing have necessitated smaller parcels of fat to be harvested to avoid higher injection pressures and clogging of the injection cannulas (►Fig. 3). We have not noticed any difference in outcome with the harvesting cannula change. The amount of fat harvested depends on the recipient requirements as well as the quality of the fat removed and procedural experience. In general, a minimum of 120 mL is harvested, but as much as 200 or more may be required. If harvested fat is hemorrhagic or oily, more harvested fat will be required to produce a similar yield. The technique of harvesting requires that gentle negative pressure is placed by withdrawing the plunger on a 10 mL syringe no more than 2 to 3 mL at a time (►Fig. 4). The cannula is then moved into and out of the donor area aspirating fat in an even plane over the entire area being aware where the tip of the cannula lies and taking care not to create any contour irregularities. While some esthetic benefit may occur at the harvesting site in thinner patients, in our practice harvesting is only performed as a necessary way to acquire viable adipocytes for grafting and body contouring is not part of the discussion.

Processing

Processing of the harvested fat has been debated and studied extensively. For the most part, no significant difference in outcome has been reported. Our practice utilized a centrifuge to process fat for several years, but several years ago we switched to the Puregraft system from Cytori (►Fig. 5A, B). The justification for the change was that in certain patients with oily or hemorrhagic aspirate, the postcentrifuged product was still not pure in its appearance. In fact, fat processed by centrifuge and then placed into the Puregraft system will create a more concentrated product and a study has recently reported a benefit in outcome utilizing the Puregraft system over centrifugation¹² (►Fig. 5A, B). A minor adjustment must be made when using the Puregraft in that because the fat becomes such a concentrated product, larger harvesting volumes, consistent with described earlier, are necessary to produce the same volume to be grafted. Because of the added expense of the Puregraft; however, we do utilize fat rinsing techniques utilizing a tea strainer from Williams and Sonoma (San Francisco, CA) and Lactated Ringers for small regional or touch-up fat transfers. The Puregraft system processing is performed by injecting the full 10 mL syringes of aspirate into the filtration bag followed by adding an equal amount of Lactated Ringers solution. The aspirate is then allowed to gravity drain for 3 minutes. A second rinse is then performed the same way. On rare occasions, for extremely oily aspirates,

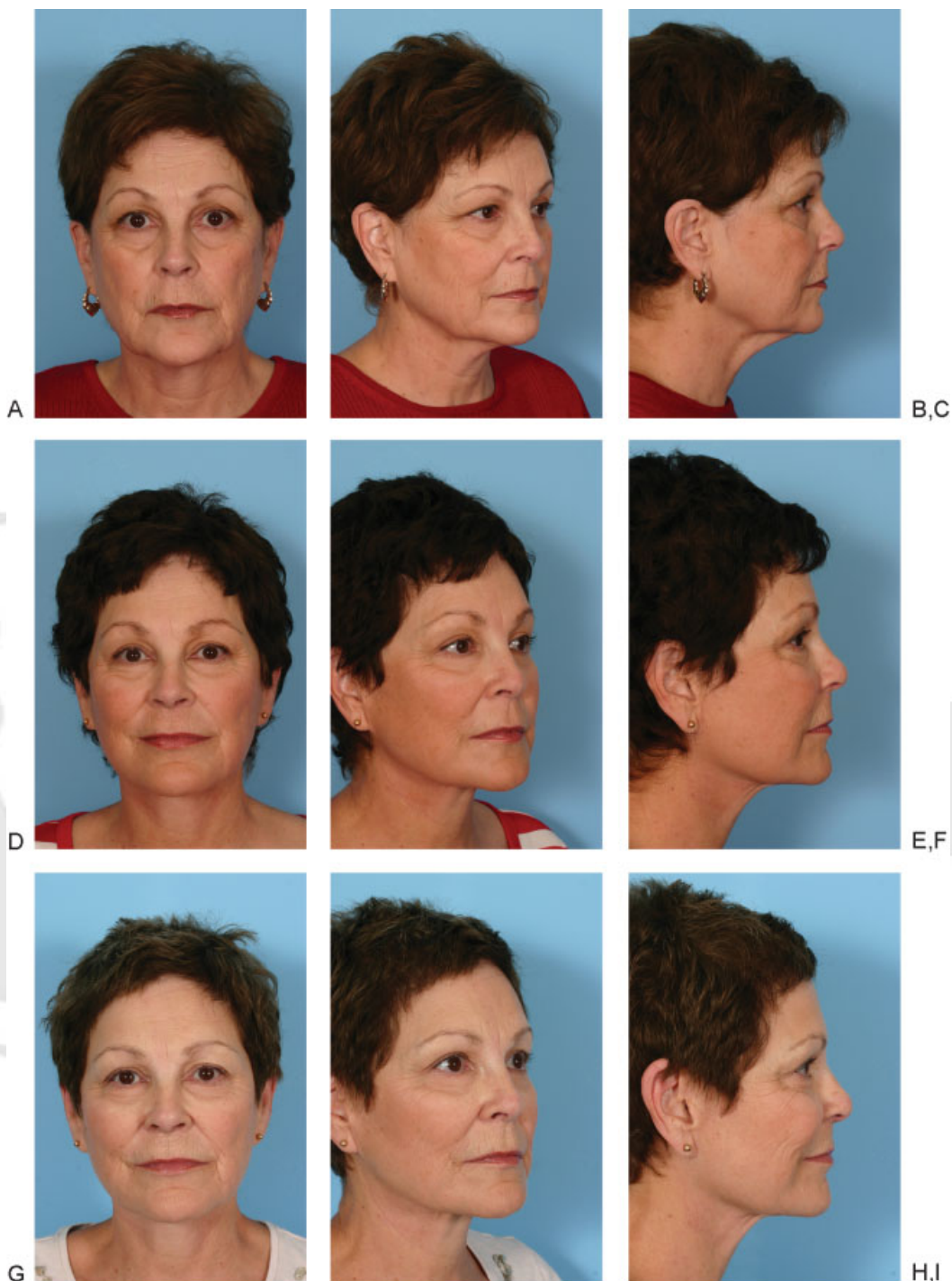

Fig. 1 Frontal, oblique, and lateral views of patient who underwent upper eyelid blepharoplasty, full face autologous fat transfer, full face trichloroacetic acid (TCA) chemical peel and lower facial rhytidectomy: (A–C) pre-op, (D–F) 2 years post-op, and (G–I) 5 years post-op.

a third rinse will be performed to produce what appears to be a fully concentrated and adequately purified product.

Injection Instruments and General Concepts

We utilize three cannulas for injection, 1.2 mm × 6 cm spoon tip cannula (Tulip Medical [San Diego, CA]), 0.9 mm × 4 cm spoon tip cannula (Tulip Medical) and a Donofrio 16-gauge straight blunt tip cannula (Byron Medical [Tuscon, AZ]) (→Fig. 3). We perform a transconjunctival lower eyelid tech-

nique if removal of lower eyelid fat is necessary. This determination is made by viewing the patient from the lateral view in consultation and if the lower eyelid fat pseudoherniation is anterior to the desired lower eyelid contours, then a small amount of fat is removed. A preseptal approach is performed and dissection is limited in its inferior extent to prevent communication with the space utilized for fat grafting. The lower eyelid procedure should be performed before fat grafting as once grafting is performed the lower eyelid becomes taut and a transconjunctival approach is much more

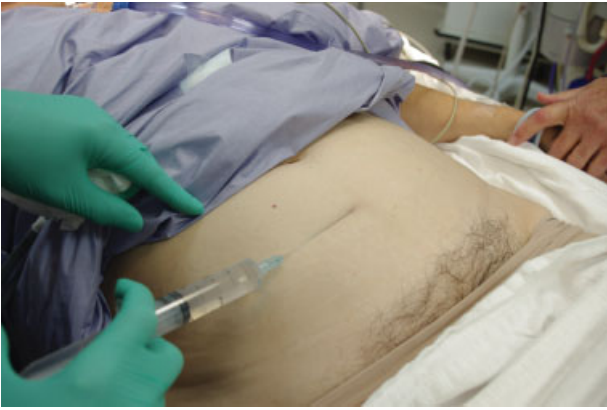

Fig. 2 Injection of Xylocaine for harvest.

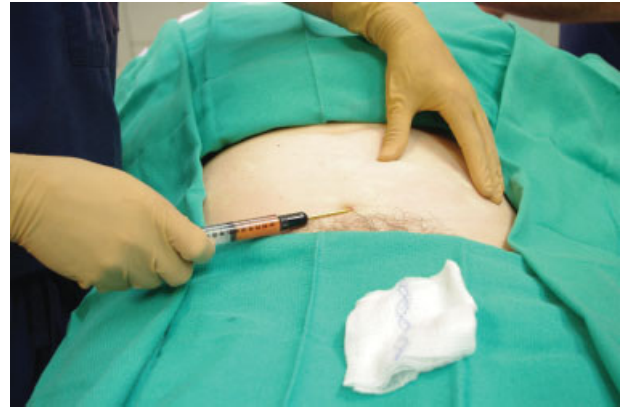

Fig. 4 Harvesting abdominal fat.

difficult. Other surgical procedures planned are all performed immediately following fat grafting. Local anesthesia is performed by placing a small aliquot of 1% Xylocaine with 1:100,000 epinephrine over the infraorbital, supraorbital, and mental nerve foramina. A small amount is also placed in the subcutaneous space at the entry sites of the anterior cheek, lateral canthal area, forehead laterally and medially, brow if upper eyelid grafting is performed, midmandible and corners of the mouth (► **Fig. 6**). Infiltration is in very minute amounts to prevent distortion of the tissues and interference of appearance of actual facial volume. The general concept of the grafting is to take areas of obvious volume deficiency and fill those first. The best example of this is the lower eyelid/cheek junction (orbital groove) and the malar groove. Once the orbital groove is adequately filled the deficiency of the lateral canthal area will become evident and need to be filled to provide balance. Similarly, as the superior orbital rim is filled, the forehead and the temple region will “show” their volume deficiency, and grafting is performed in these regions to provide balance (► **Fig. 7**). Overall, the grafting procedure is like reverse sculpting. Instead of removing stone or clay to achieve the desired result, fat is added to the face in sequential steps whereby filling one area defines the overall deficiency of the surrounding areas and these adjacent areas should be additively sculpted until facial balance is achieved. In general, areas of loss should be approached from a tangential location

and linear filling is to be avoided. The best example of this is the lower orbital rim. Approaching the rim from lateral has a high likelihood of producing a “worm-like” deposition of fat that is displeasing to the eye of the patient and on-lookers. The lower eyelid should rather be approached from the anterior cheek below the rim to allow fat to be placed across the entire rim in a balanced way. Other areas should be approached from similar vectors. Because there is always an adipocyte loss to some degree, the face is overfilled slightly, estimated to be 20 to 30% to allow for this loss. We do not advocate adding volumes of fat to the face that could ever result in an appearance of global overfilling as removing grafted fat can prove challenging if not impossible and secondary grafting or additive syringe-based fillers can always be performed. It is our belief that perioral, that is, nasolabial fold, marionette lines, and lip fat grafting is highly unreliable. The thought is that the perioral area is the most mobile area of the face and even with conscious effort is difficult to remain immobile. Also, the perioral area is like a curtain with soft tissue inside, and in contrast to the other areas of the face with a stable bony platform outside. The analogy is that of a skin graft where graft failure will occur with shearing forces. It is believed, although not confirmed, that the shearing forces of the mobile perioral area prevent reliable vascular in-growth leading to eventual graft failure. We educate our patients that while we will add fat to these areas, they should expect none to survive and that syringe-based fillers will need to be used in these areas. Occasionally, we have experienced some long-term benefit to perioral fat grafting, but the occurrence is so rare that we feel it best not to lead patients to believe it will succeed.

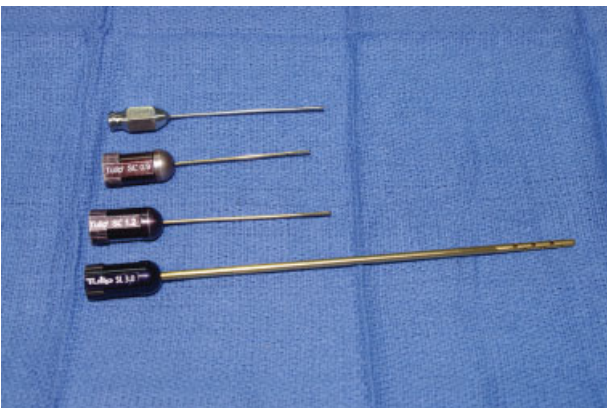


Fig. 3 Harvesting and injection cannulas.

Lower Eyelid and Lateral Canthus

Fat grafting is begun by utilizing the 1.2 mm Tulip cannula to place 1 mL of fat over the medial half of the lower eyelid/cheek junction. The injection is performed in a deep plane under the orbicularis muscle and over the periosteum by placing the index finger of the nondominate hand just inside of the orbital rim and “bouncing” the tip of the cannula off the finger as small aliquots fat are injected (► **Fig. 8**). Overall, 1 mL of fat is then transferred to the lateral half of the rim in the

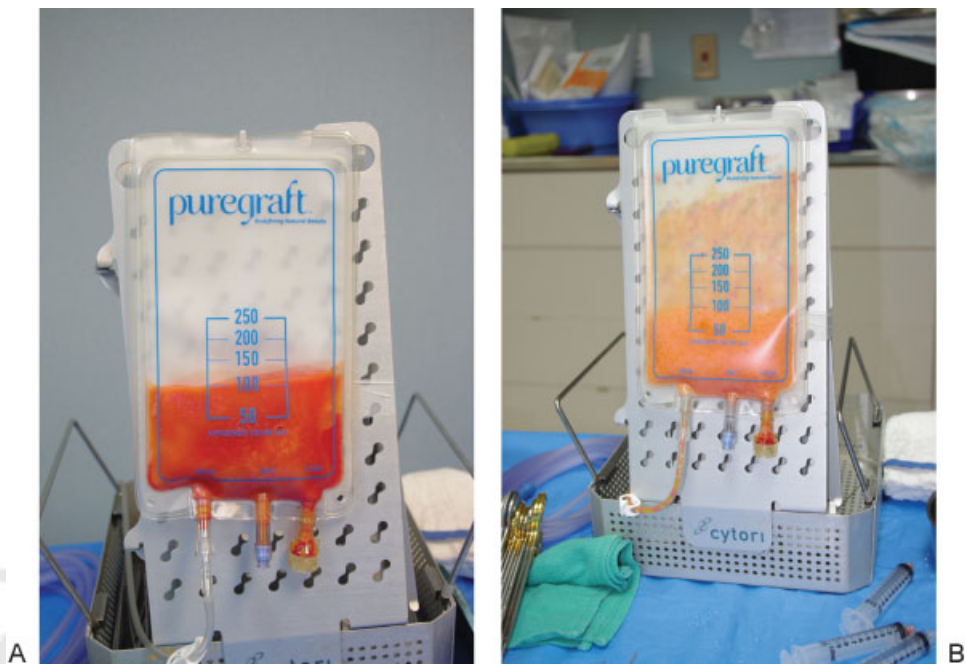


Fig. 5 (A) Appearance of harvested fat (100 of a total of 200 mL). (B) Appearance of fat after two rinses.

same plane. The contour is then inspected and up to 0.5 mL of fat added to each half in a similar plane followed by further grafting of 1 to 3 additional mL using a 0.9 mm cannula in a somewhat more superficial plane, but not in the immediate

subdermal plane as the skin in this area is too superficial to adequately conceal transferred fat. The average amount of fat placed in the lower eyelid orbital groove is 3 to 4 mL, but as much as 6 mL may be necessary. The smaller volumes are

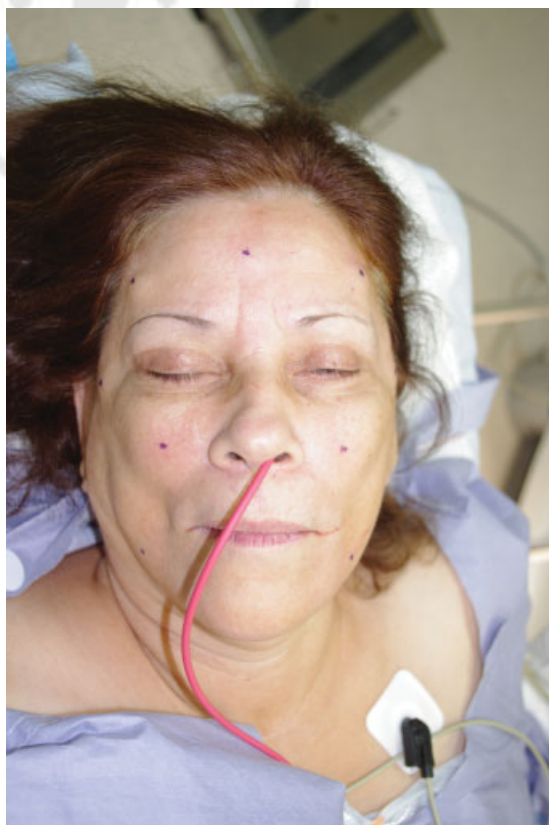

Fig. 6 Entry sites for fat grafting.

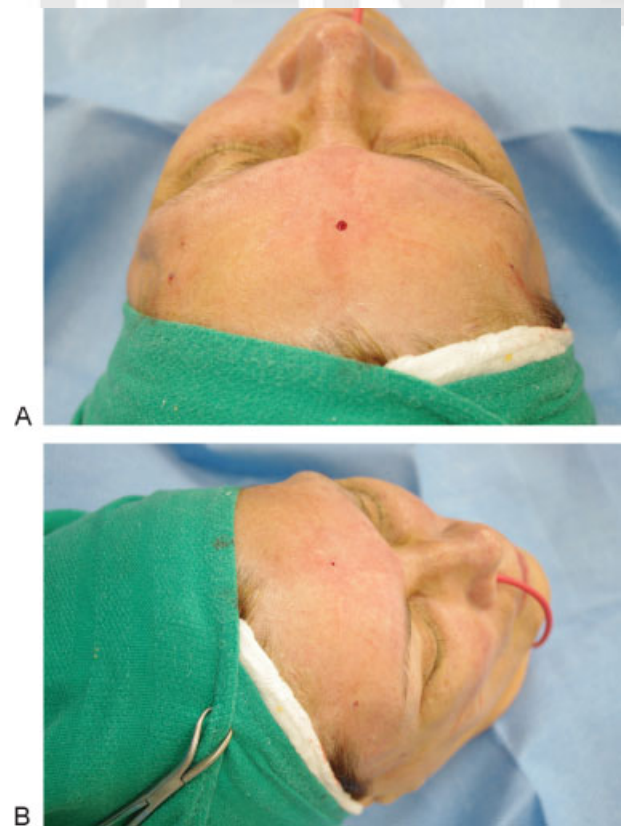


Fig. 7 (A) Photo demonstrating temple volume deficiency appearance after brow and forehead volume added. (B) Balanced appearance of face after temple grafting.

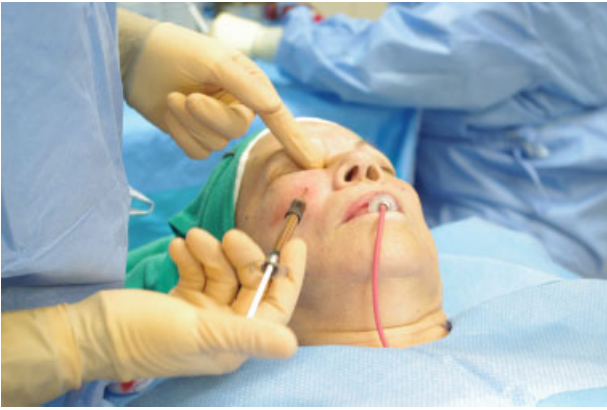


Fig. 8 Deep filling inferior orbital rim.

advised for neophyte injectors. Once the lower orbital rim has been adequately filled, the area around the lateral canthus will evolve and appear that the orbital rim fat needs to be blended in. The fat is then grafted in 1 to 2 mL quantities through a lateral periocular rhytid entry site to the lateral canthal region.

Superior Orbital Rim/Glabella, Forehead, Temple, and Upper Eyelid

At times, the lower eyelid and cheek is the only region requiring volume and at this point the anterior and lateral cheek are grafted only as described later. In most cases however, the upper facial areas are also volume deficient and grafting is performed in that region next. The superior orbital rim is approached through a lateral forehead entry site. A 1.2 mm cannula is used for all upper face injections barring the upper eyelid sulcus where 0.9 is utilized. The fat is placed over the rim in much the same fashion as the lower orbital rim using nondominant hand tactile feedback. Overall, 1 to 2 mL is placed over the lateral rim (→ Fig. 9). A midline entry site is then utilized to blend the fat into the medial rim and glabellar region totaling an additional 1 to 2 mL per side. When the orbital rim is grafted adequately, the brow will have a Cro-magnon-like appearance that can be quite disturbing. However, by adding fat to the forehead in a subcu-

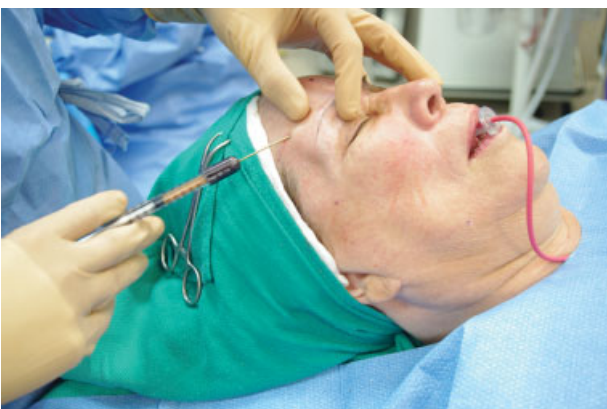

Fig. 9 Superior orbital rim placement.

taneous plane, this appearance will quickly disappear as the forehead deficiency is filled and the entire upper face blended into the volume restored orbital rim. Much like the forehead, the temple region will now look even more volume deficient and utilizing the lateral periocular entry site the temple is filled in a subcutaneous plane to balance the surrounding areas. The subfascial plane may also be utilized, but we have found better outcomes in a more superficial plane with less bleeding. Upper eyelid sulcus grafting may take place at this time utilizing an entry site in the brow. Specific conversation about this area is advised to the patient during the consultation as many will not understand the concept of a volume-restored upper eyelid and some may be displeased with the outcome. Comparing youthful photos of the patient is useful to explain to them how their upper eyelid had more volume in youth, assuming they have not had a deep sulcus naturally. In our experience however, even with an explanation, many women prefer more tarsal show rather than a full lid and opt for an upper eyelid skin removal rather than volume restoration. If volume replacement is chosen, approximately 0.5 to 1.0 mL of fat is placed into the upper sulcus starting in the infrabrow and working inferiorly. This area is an advanced technique and not advised at the outset.

Cheek and Perioral Area

At this point, we change to the Donofrio cannula as it has more rigidity and the rapidity of the remaining injections may bend the more fragile smaller cannulas. Cheek fat injection depth is from immediate sub-Q to pre-periosteal with the goal of spreading the adipocytes as diffusely as possible to maximize each cells contact with native vasculature. The malar groove in the anterior cheek is approached from the lateral periocular entry site. Overall, 1 to 2 and up to 3 mL is placed in this location adding anterior projection to the cheek and filling the hollow between the medial superficial cheek fat and the lateral malar area. Similarly, the lateral cheek is then filled from the anterior cheek entry site starting superiorly, blending the lateral canthal area into the zygomatic arch area, malar prominence, and anterior cheek. Overall, 1 to 3 and at times even 4 mL of fat is placed into this region. The finished cheek should have a maximal light reflection point over the malar prominence, blend naturally to all the surrounding areas, and create a subtle submalar shadow parallel to the mandible. At this time, the buccal area may appear to be deficient and 1 to 3 mL may bring it into balance, however, use of upright preoperative photos is advised at this time and if the patient had any degree of fullness preoperatively in this area, the buccal area is left ungrafted as recumbence accentuates the appearance of volume deficiency in this area, and creating a submalar shadow is quite appealing for most women in particular. We usually lift the cheek as if simulating a rhytidectomy and if the buccal area and cheek assume a desirable appearance then the buccal area is left alone or only blended into the cheek fat to eliminate any harsh transitions.

Mandible and Chin

Attention is now turned to the lower face and perioral area. Although perioral grafting has had limited success with long-term results, the benefit of a short-term result with the possibility of some long-term benefit warrants grafting in this area. The canine fossa is therefore grafted routinely with 1 mL of fat with the intention of lifting the lateral alar area of the base of the nose in the pre-periosteal plane. 1 mL is then placed in each nasolabial fold and 1 mL in the upper perioral cutaneous lip. Grafting is then turned to the mandible and prejowl sulcus, which being over a bony prominence and in a relatively immobile location tends to offer more predictable longevity. An entry site along the lower mandible and lateral to the prejowl sulcus is created and 2 to 3 mL of fat is placed along the mandible filling the prejowl sulcus both laterally and to a variable extent inferiorly. The fat is then added to the marionette area from the same entry again realizing that the longevity is the exception in this area. If desired, a small stab incision is then created at each oral commissure and 0.5 to 1 mL of fat is placed in each mucosal lip quadrant with the 0.9 mm cannula. On rare occasions, the lateral mandible can also be grafted in a similar fashion to the prejowl sulcus; however, this is not usually performed concurrently with a rhytidectomy. This completes the grafting procedure and other surgical interventions may proceed.

Summary

Volume loss is thought to be an important part of the aging process with the esthetic industry and providers spending large amounts of time, energy, and financial resources developing techniques and products to restore youth through replacing volume. Facial autologous fat grafting has become an important tool in volume replacement for the right

patient, and better techniques have led to more reliable and reproducible long-term outcomes. Continued research and refinement of technique will likely lead to even better graft survival and predictable outcomes.

References

- 1 Lambros V. Observations on periorbital and midface aging. *Plast Reconstr Surg* 2007;120(5):1367–1376, discussion 1377
- 2 Lambros V. Models of facial aging and implications for treatment. *Clin Plast Surg* 2008;35(3):319–327, discussion 317
- 3 Obagi S. Specific techniques for fat transfer. *Facial Plast Surg Clin North Am* 2008;16(4):401–407, v
- 4 Lam SM, Glasgold MJ, Glasgold RA. *Complementary fat grafting*. Philadelphia, PA: Lippincott Williams and Wilkins; 2007
- 5 Coleman SR. Structural fat grafting: more than a permanent filler. *Plast Reconstr Surg* 2006;118(3, Suppl):108S–120S
- 6 Coleman SR. *Structural fat grafting*. St Louis, MO: Quality Medical Publishing, Inc; 2004
- 7 Glasgold RA, Glasgold MJ, Lam SM. Complications following fat transfer. *Oral Maxillofac Surg Clin North Am* 2009;21(1):53–58, vi
- 8 Gir P, Brown SA, Oni G, Kashefi N, Mojallal A, Rohrich RJ. Fat grafting: evidence-based review on autologous fat harvesting, processing, reinjection, and storage. *Plast Reconstr Surg* 2012;130(1):249–258
- 9 Pessa JE. An algorithm of facial aging: verification of Lambros's theory by three-dimensional stereolithography, with reference to the pathogenesis of midfacial aging, scleral show, and the lateral suborbital trough deformity. *Plast Reconstr Surg* 2000;106(2):479–488, discussion 489–490
- 10 Rohrich RJ, Pessa JE, Ristow B. The youthful cheek and the deep medial fat compartment. *Plast Reconstr Surg* 2008;121(6):2107–2112
- 11 Shaw RB Jr, Kahn DM. Aging of the midface bony elements: a three-dimensional computed tomographic study. *Plast Reconstr Surg* 2007;119(2):675–681, discussion 682–683
- 12 Gerth DJ, King B, Rabach L, Glasgold RA, Glasgold MJ. Long-term volumetric retention of autologous fat grafting processed with closed-membrane filtration. *Aesthet Surg J* 2014;34(7):985–994